

Francesco Pisani
Carlo Fusco

Ictal and interictal EEG findings in children with migraine

Received: 9 August 2002
Accepted in revised form: 10 December 2003

F. Pisani (✉) • C. Fusco
Department of Pediatrics,
Service of Child Neuropsychiatry,
University of Parma,
Via Gramsci 14, I-43100 Parma, Italy
e-mail: francesco.pisani@unipr.it
Tel.: +39-0521-702750
Fax: +39-0521-290458

Abstract We describe the electroencephalographic findings in nine pediatric migraineurs during the ictal phase of pain. We observed abnormal patterns on electroencephalography (EEG) in seven patients with migraine with aura and in two patients with basilar migraine. These patients were also evaluated with EEG during headache-free interval, at least 7 days after the ictal event; these interictal findings were unremark-

able, confirming the observations reported in the literature. Finally, we review migraine and its EEG characteristics as reported in the literature, and discuss the value of EEG performed during interictal and ictal phases of migraine.

Key words Electroencephalography • Migraine • Aura • Basilar migraine • Ictal phase • Interictal phase

Introduction

During the last 50 years, a variety of electroencephalographic abnormalities have been described in patients with different types of migraine [1], with a reported incidence ranging from 11% to 74% [2–6]. The great majority of these studies referred to interictal electroencephalography (EEG) and mainly are based on adult patients, while only a few EEG studies have been conducted during the acute phase of headache in children. Several EEG patterns dependent on age, type of migraine and clinical phase of symptoms have been reported. De Carlo et al. [2] underlined that about 80% of 40 (32/40) children and adolescents presented abnormalities in the critical phase compared to 4.4% during the intercritical period. Puca and de Tommaso [3] reported that the EEG abnormalities in children were quite aspecific, while more definitely altered EEG patterns consisting of spike or high voltage delta activity had been observed in smaller series.

Intercritical EEGs with aspecific abnormalities and no neurophysiological differences between children migraineurs with and without aura, during the headache-free period, have been described [2–4, 6–8].

Ramelli et al. [5] observed marked interhemispheric alpha asymmetry, sometimes associated with an increment of delta activity, during migraine attacks with sensorial or visual aura, while during the acute attack of migraine without aura EEG usually revealed an increase of slow activity on posterior regions. Other EEG patterns, including focal or diffuse slowing that resolves several days after the attack have been described even in rare migraine forms such as hemiplegic or basilar migraine, during ictal phase [4, 5].

To clarify whether pediatric migraineurs exhibit electroencephalographic abnormalities and to further understand the diagnostic utility of such observations, we performed EEG during the acute and intercritical phases of migraine attack in 9 young people referred consecutively to the Emergency Pediatrics Department of the University of Parma. Furthermore, we discuss our data on the basis of the current literature exclusively focused on pediatric age.

Patients and methods

We performed electroencephalography (EEG) in children and adolescents referred consecutively in 2003 for acute migraine attack to the Emergency Pediatrics Department. Migraine headache was diagnosed according to the diagnostic criteria proposed by the International Headache Society [9]. EEG was performed at the Neurophysiology Laboratory of the Neuropediatric Unit. In all patients, EEG was performed within 3 h of onset of the headache attack (range, 0–3 h) and all subjects were still symptomatic (suffering from head pain) during the EEG examination. After the EEG recording session, the patients were administered paracetamol to stop the acute attack. Subsequently, the patients underwent physical and neurological examinations and another EEG examination out of the acute phase (at least 7 days after the attack and at least 10 days before the following attack).

EEG was performed on a 21-channel Nicolet machine. An electrode cap based on the International 10–20 System for the lead position was used, and each recording session lasted for a minimum of 40 min, with 3 min of hyperventilation and intermittent photic stimulation (IPS) obtained with a flash frequency ranging from 1 to 30 Hz. The electroencephalograms were evaluated visually by the same neurophysiologist (F.P.), and then inspected by another physician (C.F.) blinded to the patients' identities. There was no interobserver variation in the interpretation of the traces.

Results

We present the EEG findings in 9 patients, including 6 girls and 3 boys, of mean age 12.9 years (Table 1). These

Table 1 Clinical characteristics and EEG findings in 9 pediatric patients with migraine

Patient	Sex	Age, years	Diagnosis	Duration of pain, h	Family history	Other symptoms	Intensity of pain	Visual aura	Sensorial aura	EEG findings
1	F	15	MA	3	No	No	Severe	Blurred vision of the left visual field	Paresthesias of left arm	Delta-theta activity on right occipital region
2	F	13	MA	4	No	No	Severe	No	Paresthesias of left hemiface and tongue	Delta-theta activity on temporo-occipital regions (right) Marked slowing during hyperventilation
3	M	16	MA	4	MA	No	Moderate	Left temporal hemianopsia	No	Theta waves on right parieto-occipital regions
4	F	14	MA	3	M	No	Moderate	Blurred vision, No zigzag pattern of right visual field	No	Delta-theta waves on left temporal regions
5	F	10	MA	3	MA	No	Moderate	Blurred vision, No zigzag pattern of right visual field	No	Delta waves on left posterior regions
6	F	14	MA	4	No	No	Severe	No	Paresthesias of left arm	Delta-theta activity on right occipital region. Bursts of sharpish transients at 7–10 cycles/s on central regions Photodriving (right>left) during IPS
7	M	7	MA	4	M	No	Severe	Blurred vision of left visual field	No	Delta-theta activity on right occipital region
8	M	13	BM	6	MA	Vertigo, dysarthria, ataxia	Severe	Bitemporal hemianopsia	No	Asymmetry of background activity and high-amplitude delta activity on right occipital regions
9	F	14	BM	8	No	Vertigo, dysarthria, altered consciousness	Severe	No	Paresthesias of the arms	Asymmetry of background activity and high-amplitude delta activity on right occipital regions

MA, migraine with aura; BM, basilar migraine; M, migraine without aura; IPS, intermittent photic stimulation

subjects had previously been referred to our headache outpatient clinic before being studied at emergency admission. Seven of these patients had migraine with aura and two had basilar migraine. Two patients with migraine with aura and one with basilar migraine had a family history of migraine with aura (mothers suffering from headache). In all subjects, the frequency of headache was >2 attacks per month and the duration of each episode was >3 hours. No patient was taking prophylactic pharmacological treatment for migraine.

We observed EEG abnormalities in all patients during the acute phase (Table 1).

During acute attacks in patients with migraine with aura, the EEG abnormalities were characterized by the presence of an excess of focal slow activity in the delta or theta range (Fig. 1). This was localized on the posterior (parietal and occipital) or temporal regions, contralaterally to the symptomatic hemibody involved in the aura phase with no peculiar

differences regarding the type of aura (visual or somatic). Moreover asymmetry of background activity was present and we never observed any epileptiform transients. No other clear abnormalities were observed except diffuse slowing during hyperventilations in two patients and bilateral photodriving during IPS in a third patient.

The electroencephalograms recorded during the attack in two patients with basilar migraine (Table 1) showed asymmetric background activity and irregular high-amplitude delta activity over the right posterior regions (Fig. 2). This pronounced, focal slow activity increased during hyperventilation, but no peculiar reaction upon IPS was seen.

In all patients, no EEG abnormalities were found during the headache-free interval, at least 7 days after the acute headache attack and at least 10 days before the following attack. Furthermore, there were no abnormal findings on physical and neurological examinations during the headache-free period.

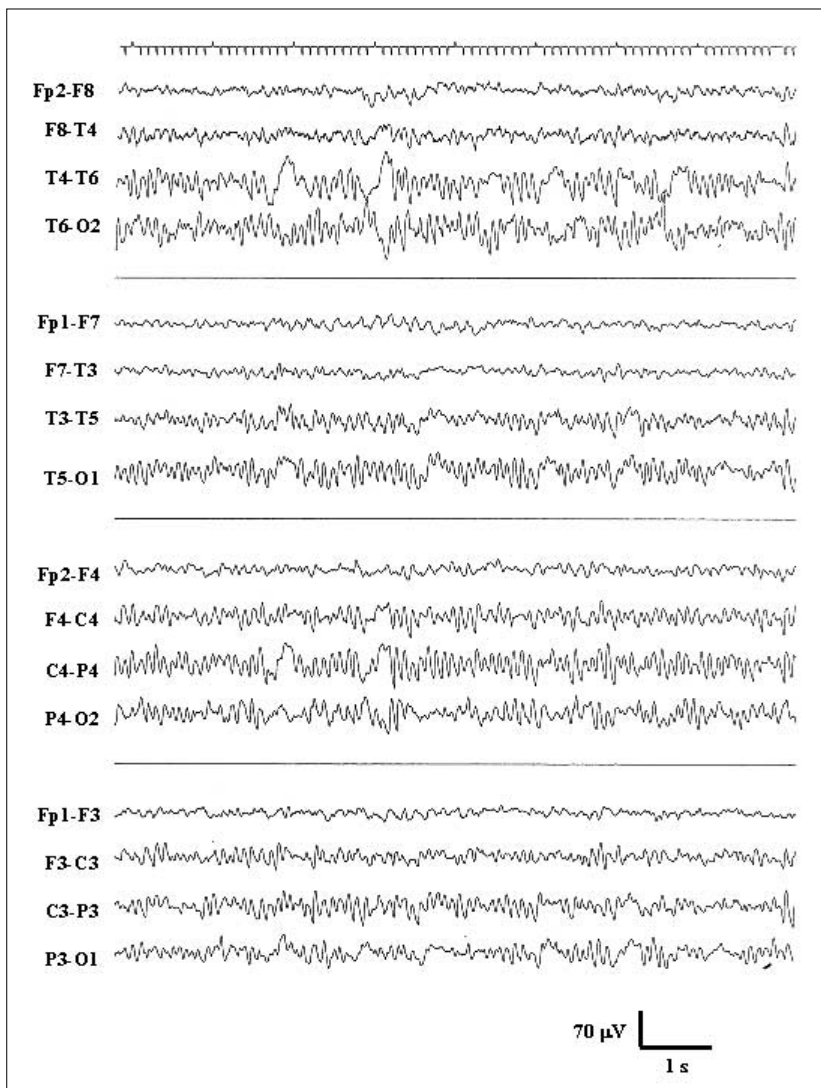


Fig. 1 EEG pattern in patient n. 2 with migraine with aura (female, 13 years). See delta activity on the right posterior regions

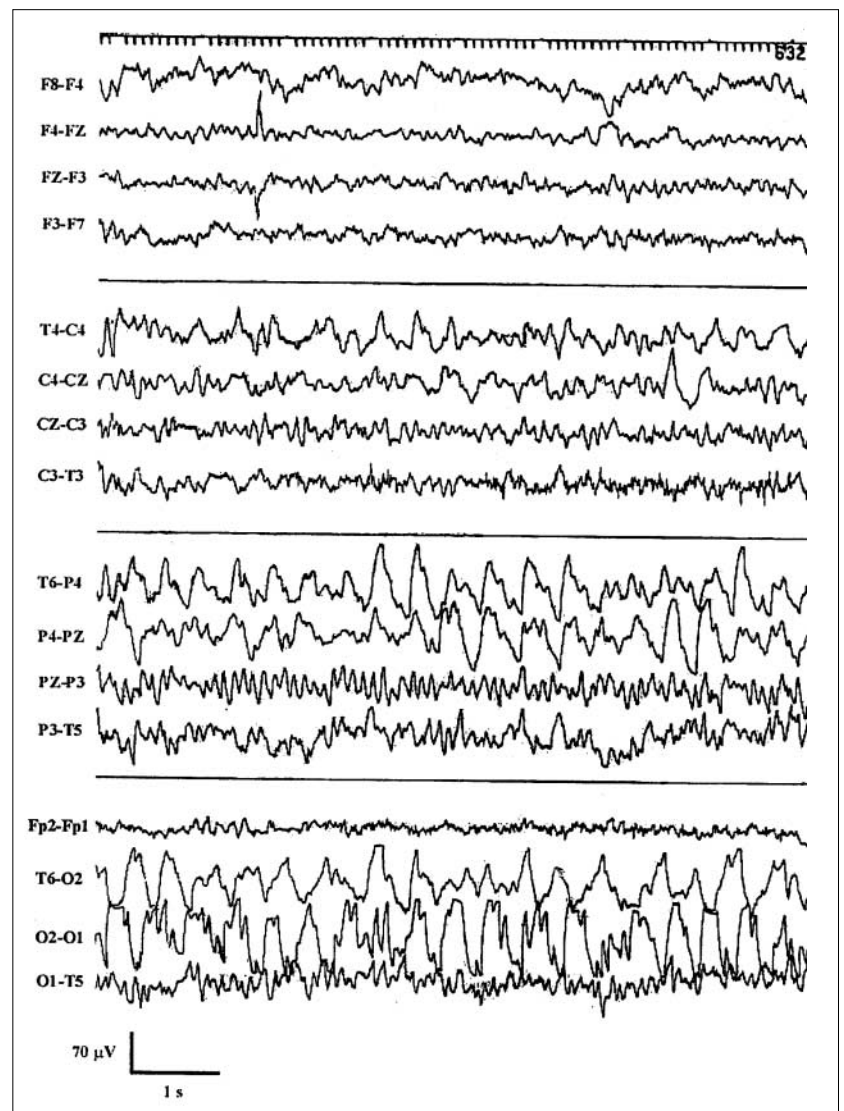


Fig. 2 EEG pattern in patient n. 8 with basilar migraine (male, 13 years). See irregular high-amplitude delta activity on the right posterior regions

Discussion

Previous reports [3, 10, 11] described, in the intercritical phase, an increased theta rhythm with an alpha interhemispheric asymmetry in patients with both migraine with and without aura. These abnormalities have usually been observed contralaterally to the hemibody clinically involved. We used as controls the same patients during the headache-free period, at least 7 days after the onset of headache: no significant EEG abnormalities were observed during interictal phase.

The literature [2, 3, 8, 12, 13] underlines the presence, during the acute phase, of unilateral slowing and asymmetry of the dominant frequency in the alpha range that our study only partially confirms. Moreover, background EEG activity has been studied even by means of comput-

er-assisted quantitative analysis and revealed essentially fluctuating abnormalities dependent on age, type of migraine, and time from the last attack [3]. The main quantitative EEG abnormalities reported [3, 6, 8] are the slowing and asymmetry of the alpha frequency; specifically, during attacks of migraine without aura, the alpha rhythm interhemispheric index is increased in frontal and central regions, while with attacks of migraine with aura, this alpha rhythm suppression is observed in the occipital regions contralateral to the affected hemifield, with an increase of delta activity on the posterior regions. Minimal regional differences with lower power in alpha range have also been reported in patients with classic migraine during symptoms-free phase [14]. Furthermore, Nyrke et al. [15], Jonkman and Lelieveld [16] and Facchetti et al. [17] reported frequency asymmetries of the alpha rhythm in patients with classic migraine.

Schoenen et al. [18] showed no abnormalities in migraineurs (with and without aura) who underwent spectral analysis and topographic EEG mapping in intercritical phase. Sand [4] in his review confirmed that inconsistent intercritical EEG findings have been reported; however a pattern of increase alpha rhythm variability emerged from the several studies analyzed.

In our sample we never disclosed EEG abnormalities during the interictal phase, confirming that this diagnostic procedure has no clear indication in this phase.

During the acute attack of migraine with aura, Schoenen et al. [18] reported posterior-anterior spreading of slow activity and depression of alpha or theta activity contralateral to the neurological signs, while in patients with common migraine, they recorded reduced alpha activity over one occipital region, usually on the side of the headache. Soriani et al. [19] reported the case of an 11-year-old boy with recurrent migraine auras without headache; ictal EEG recordings showed a continuous and diffuse beta activity with disappearance of the alpha rhythm and normal interictal EEG.

In our study, in the ictal phase, we observed an excess of slow activity in the delta or theta range over the posterior regions, contralaterally to the symptomatic hemibody involved in the aura phase with no peculiar differences regarding the type of aura (visual or somatic). In two patients we also noticed an asymmetry of the amplitude of the alpha rhythm, during the acute phase of migraine with aura. These findings seem to strengthen the data obtained by cerebral blood flow studies, particularly in migraine patients with aura, that show a reduction in regional flow that generally begins in the posterior regions and spreads anteriorly [20]. This observation suggests that we need to use different diagnostic procedures to better investigate cerebral blood flow during the attack.

A pronounced slowing during hyperventilation in migraineurs has often been described; however, this response is variable and frequently marked in children [3, 6]. The distinction between normal or abnormal response is a personal point of view; in fact there are no strict criteria to follow on this regard, so we decided not to use the findings during hyperventilation in this study.

The most intriguing EEG abnormality found in patients with migraine is epileptic activity that was found with an incidence ranging from 0.4% to 20% [11]. This epileptic activity includes generalized and focal discharges during rest and during photic stimulation and hyperventilation; high-voltage spike-wave complexes, suppressed by eye opening, have been observed in migraine with visual aura and also in basilar migraine, childhood epilepsy with occipital paroxysm and benign rolandic epilepsy [3, 6, 7, 21–25]. Panayiotopoulos [26, 27] reviewed clinical and EEG criteria of occipital epilepsy

and migraine with aura and concluded that if each characteristic of visual aura is identified (duration, color, shape, size, location, movement, speed of development and progress), the diagnosis is easy. Recently, Brinciotti et al. [28] showed that the presence of specific clinical features (amaurosis, scotoma and family history of migraine), together with bilateral EEG abnormalities and no changes during IPS, is related to migraine. Furthermore, some authors [3, 6, 7] reported epileptic abnormalities in children suffering from chronic headache. In a recent report, periodic lateralized epileptiform discharges (PLEDs) were observed in adult patients with migraine [29]. We did not see any epileptiform transients in our subjects during attack or in the headache-free interval. However in our cases the clinical and symptomatic history allowed us to easily exclude a co-existence of headache and epilepsy.

Other EEG abnormalities have been reported in basilar migraine, a variant of migraine with aura [5, 9, 30]. In 1961 Bickerstaff [31–33] described basilar migraine as a type of migraine with aura, and in 1968 Slatter described the EEG findings during the ictal phase [34]. Parain and Samson-Dollfus [35] described an excess of beta activity in the ictal EEG of children with attacks of basilar migraine. Passier et al. [36] showed predominant delta activity in the same patient during several attacks and normal activity between them. Ramelli et al. [5] showed diffuse polymorphic subdelta-delta activity in two patients with basilar migraine and delta-theta activity predominant over the occipital regions in another two subjects. However, during ictal phase, bilateral high-voltage posterior slowing [37–42] and posterior delta slowing associated with spikes and sharp waves or posteriorly predominant sharp and slow wave complexes [43, 44] have also been described. Finally, Pietrini et al. [45] reported an unusual association of acute confusional migraine and frontal intermittent rhythmic delta activity (FIRDA).

In our patients, EEG performed 3 h after symptoms onset showed high-amplitude delta activity over the right posterior regions with asymmetry of the background activity. Once again, no abnormalities were found during the interictal phase, in agreement with other studies.

In conclusion, our study confirms, in agreement with other authors [2], that in the headache-free interval there is no significant variation in EEG pattern in two different types of migraine. We believe that in intercritical phase, EEG does not add further information to the clinical and neurological examination of a patient. EEG can be helpful to rule out cerebral lesions such as inflammatory processes or cerebral tumors with a clear relationship to the clinical features. Moreover, EEG could be useful in the differential diagnosis between epilepsy and migraine in children with occipital epileptiform EEG abnormalities [28]. The EEG pattern in children with migraine observed by

some authors could be explained by the possible persistence of critical abnormalities in the asymptomatic phase; these are detectable in adults with migraine with aura and in both types of migraine during juvenile age. This difference may be due to the electrophysiological instability of juvenile age interacting with the basic mechanism underlying the disease, but which remains to be determined [3, 8]. However, we never observed abnormalities during the interictal phase and this could be explained by the fact that we performed the second EEG examination at least 7 days after the acute phase.

We noticed some abnormalities during the acute phase in migraine with aura and in basilar migraineurs. The evo-

lution of the EEG abnormalities that disappeared during the headache-free interval in all patients and the clinical findings suggest that we must avoid misinterpretation of these features, bearing in mind that the slow activity during the migraine attack should not be necessarily identified as sign of a structural brain lesion. These findings confirm that performing a routine EEG examination during the interictal phase is probably not useful, while ictal EEG represents a valuable, noninvasive technique that can show transient neuronal changes induced by migraine attack.

Acknowledgement We thank Professor L.A. Pini for his helpful suggestions on earlier drafts of the manuscript.

References

- Lauritzen M, Trojaborg W, Olesen J (1981) EEG during attacks of common and classical migraine. *Cephalalgia* 1(2):63–66
- De Carlo L, Cavaliere B, Arnaldi C, Faggioli R, Soriani S, Scarpa P (1999) EEG evaluation in children and adolescents with chronic headaches. *Eur J Pediatr* 158(3):247–248
- Puca F, de Tommaso M (1999) Clinical neurophysiology in childhood headache. *Cephalalgia* 19:137–146
- Sand T (1991) EEG in migraine: a review of the literature. *Funct Neurol* 6(1):7–22
- Ramelli GP, Sturzenegger M, Donati F, Karbowski K (1984) EEG findings during basilar migraine attacks in children. *Electroencephalogr Clin Neurophysiol* 107:374:378
- Froelich WA, Carter CC, O'Leary JL, Rosenbaum HE (1960) Headache in childhood: electroencephalographic: evaluation of 500 cases. *Neurology* 10:639–642
- Hockaday JM, Witty CWM (1969) Factors determining the electroencephalogram in migraine: a study of 560 patients according to clinical type of migraine. *Brain* 92:769–788
- Prensky AL, Sommer D (1979) Diagnosis and treatment of migraine in children. *Neurology* 29:506–510
- (1988) Classification and diagnostic criteria for headache disorders, cranial neuralgias and facial pain. Headache Classification Committee of the International Headache Society. *Cephalalgia* 8[Suppl 7]:1–96
- De Tommaso M, Scirucchio V, Guido M, Sasanelli G, Puca FM (1998) EEG spectral analysis in migraine without aura attacks. *Cephalalgia* 18:324–328
- Kramer U, Nevo Y, Neufeld MY, Harel S (1994) The value of EEG in children with chronic headaches. *Brain Dev* 16:304–308
- Gronseth GS, Greenberg MF (1995) The utility of electroencephalogram in the evaluation of patients presenting with headache. *Neurology* 45:1263–1267
- Genco S, de Tommaso M, Prudenzeno AMP, Savarese M, Puca FM (1994) EEG features in juvenile migraine: topographic analysis of spontaneous and visual evoked brain electrical activity: a comparison with adult migraine. *Cephalalgia* 14:41–46
- Neufeld MY, Treves TA, Korczyn AD (1991) EEG and topographic frequency analysis in common and classic migraine. *Headache* 31(4):232–236
- Nyrke T, Kangasniemi P, Lang H (1990) Alpha rhythm in classical migraine (migraine with aura): abnormalities in the headache-free interval. *Cephalalgia* 10(4):177–181
- Jonkman EJ, Lelieveld MHJ (1981) EEG computer analysis in patients with migraine. *Electroencephalogr Clin Neurophysiol* 52:652–655
- Facchetti D, Marsile C, Faggi L, Donati E, Kokodoko A, Poloni M (1990) Cerebral mapping in subjects suffering from migraine with aura. *Cephalalgia* 10(6):279–284
- Schoenen J, Jamart B, Delwaide PJ (1987) Electroencephalographic mapping in migraine during the critical and intercritical periods. *Rev Electroencephalogr Neurophysiol Clin* 17(3):289–299
- Soriani S, Scarpa P, Arnaldi C, De Carlo L, Pausini L, Montagna P (1996) Migraine aura without headache and ictal fast EEG activity in an 11-year-old boy. *Eur J Pediatr* 155:126–129
- Lauritzen M, Olesen J (1984) Regional cerebral blood flow during migraine attacks by xenon-133 inhalation and emission tomography. *Brain* 107:447–461
- Panayiotopoulos CP (1989) Benign nocturnal childhood occipital epilepsy: a new syndrome with nocturnal seizures, tonic deviation of the eyes and vomiting. *J Child Neurol* 4(1):43–49
- Andermann F (2002) Migraine and the benign partial epilepsies of childhood: evidence for an association. *Epileptic Disord* 2[Suppl 1]:S37–S39
- Ballesteros Garcia S, Otero Martinez B, Langunilla Herrero L, Fernandez Zurita C, Perez Mendez C, Solis Sanchez G (2001) Idiopathic childhood occipital epilepsy. *An Esp Pediatr* 54(4):340–345
- Andermann F, Zifkin B (1998) The benign occipital epilepsies of childhood: an overview of the idiopathic syndromes and of the relationship to migraine. *Epilepsia* 39[Suppl 4]:S9–S23

25. Gastaut H (1983) A new type of epilepsy: benign partial epilepsy of childhood with occipital spike wave. *Clin Electroencephalogr* 22:13–22
26. Panayiotopoulos CP (1999) Visual phenomena and headache in occipital epilepsy: a review, a systematic study and differentiation from migraine. *Epileptic Disord* 1(4):205–216
27. Panayiotopoulos CP (1999) Elementary visual hallucinations, blindness, and headache in idiopathic occipital epilepsy: differentiation from migraine. *J Neurol Neurosurg Psychiatry* 66(4):536–540
28. Brinciotti M, Di Sabato ML, Matricardi M, Guidetti V (2000) Electroclinical features in children and adolescents with epilepsy and/or migraine, and occipital epileptiform EEG abnormalities. *Clin Electroencephalogr* 31(2):76–82
29. Garcia-Morales I, Garcia MT, Galan-Davila L, Gomez-Escalonilla C, Saiz-Diaz R, Martinez-Salio A, de la Peña P, Tejerina A (2002) Periodic lateralized epileptiform discharges: etiology, clinical aspects, seizures, and evolution in 130 patients. *J Clin Neurophysiol* 19:172–177
30. Ganji S (1986) Basilar artery migraine: EEG and evoked potential patterns during acute stage. *Hedache* 26(5):220–223
31. Bickerstaff ER (1961) Basilar artery migraine. *Lancet* 1:15–17
32. Bickerstaff ER (1961) Impairment of consciousness in migraine. *Lancet* 2:1057–1059
33. Bickerstaff ER (1964) Ophthalmoplegic migraine. *Rev Neurol*:100
34. Slatter KH (1968) Some clinical and EEG findings in patients with migraine. *Brain* 91:85–998
35. Parain D, Samson-Dollfus C (1984) Electroencephalograms in basilar artery migraine. *Electroencephalogr Clin Neurophysiol* 58:392–399
36. Passier PE, Vredeveld JW, de Krom MC (1994) Basilar migraine with severe EEG abnormalities. *Headache* 34(1):56–58
37. Cernibori A, Bouquet F (1984) Loss of consciousness during basilar migraine attack in childhood: EEG and clinical studies. *Electroencephalogr Clin Neurophysiol* 58:72
38. Bouquet F, Cernibori A (1981) Prolonged consciousness disorders in attacks of basilar artery migraine. *Rev Neurobiol* 27:671–676
39. Beaumanoir A, Jekiel M (1987) Electrographic observations during attacks of classical migraine. In: Andermann F, Lugaresi E (eds) *Migraine and epilepsy*. Butterworth, Boston, pp 163–180
40. Jacome DE (1978) EEG features in basilar artery migraine. *Am J Dis Child* 132:278–281
41. Eviatar L (1981) Vestibular testing in basilar artery migraine. *Ann Neurol* 9:126–130
42. Gascon G, Barlow CG (1970) Juvenile migraine presenting as an acute confusional state. *Pediatrics* 45:628–635
43. De Romanis F, Buzzi G, Assenza S, Brusa L, Cerbo R (1993) Basilar migraine with electroencephalographic findings of occipital spike-wave complexes: a long-term study in seven children. *Cephalalgia* 13:192–196
44. Panayiotopoulos CP (1980) Basilar migraine? Seizures, and severe epileptic EEG abnormalities. *Neurology* 30(10):1122–1125
45. Pietrini V, Terzano MG, D'Andrea G, Parrino L, Cananzi AR, Ferro-Milone F (1987) Acute confusional migraine: clinical and electroencephalographic aspects. *Cephalalgia* 7(1):29–37