

Sait Albayram  
Koray M. Tasmali  
Aysegul Gunduz

## Can spontaneous intracranial hypotension cause venous sinus thrombosis?

Received: 26 February 2007

Accepted in revised form: 20 April 2007

Published online: 11 June 2007

S. Albayram (✉) • K.M. Tasmali  
I.U. Cerrahpasa Medical Faculty,  
Department of Radiology,  
Division of Neuroradiology,  
Istanbul University,  
34300 K.M. Pasa, Istanbul, Turkey  
e-mail: salbayram@hotmail.com  
Tel.: +90-533-7482463  
Fax: +90-212-414-3167

A. Gunduz  
I.U. Cerrahpasa Medical Faculty  
Department of Neurology  
Istanbul, Turkey

Sir,

We present a 45-year-old man who had severe postural headache and high blood pressure. Postural headache had started 6 days previously and had lost postural feature in two days. Cranial magnetic resonance imaging (MRI) showed dural thickening, subdural effusion and superior sagittal sinus thrombosis. We observed diffuse epidural collections in the entire dorsal and upper lumbar area by intrathecal gadolinium-enhanced MR cisternography (Fig. 1). Therefore, he was diagnosed as spontaneous intracranial hypotension (SIH) and cerebral venous sinus thrombosis (CVST) without any determined hypercoagulable state.

Epidural blood patch (EBP) was applied because of intractable headache and diffuse spinal epidural collections. All symptoms except mild, non-postural headache improved in one day. After the blood at the epidural area matured, the patient was started on anticoagulant therapy. In one month, all symptoms improved and the MRI findings of SIH and VST disappeared completely (Fig. 2).

SIH may present with a spectrum of

symptoms [1] and MRI is known as the non-invasive diagnostic gold standard [2].

Compensatory dilatation of the venous sinuses and traction of cortical veins and venous sinuses in SIH [3, 4] lead to stasis of blood flow and subsequent tendency for thrombosis. When the patient experiences a change in the characteristics of the headache, this should alert us to CVST.

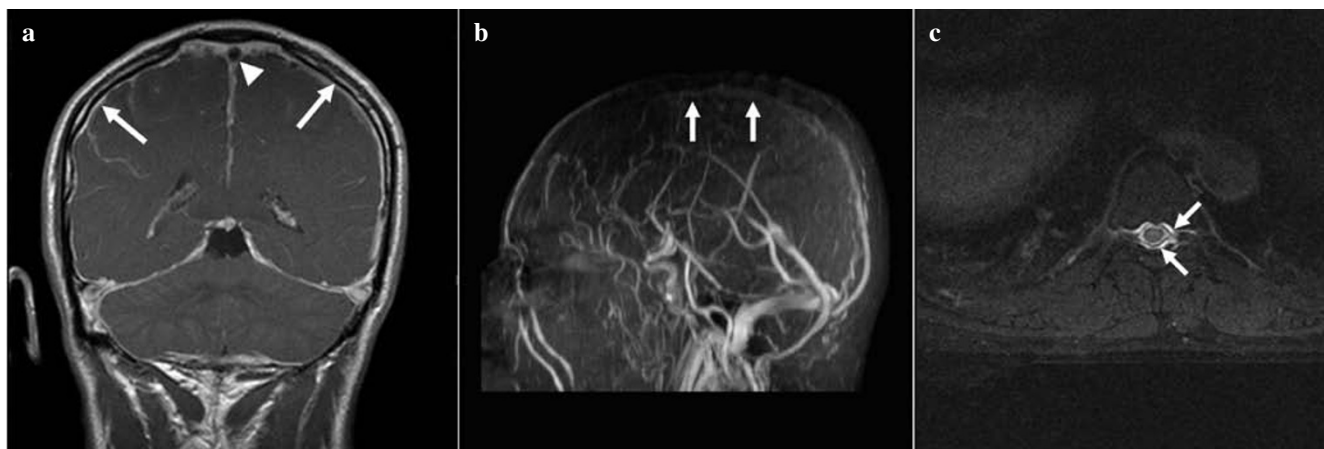
Berroir et al. [5] indicate that because their patients did not necessitate EBP, they gave priority to the treatment of CVST. Although the case of Kataoka et al. [4] was firstly treated with anticoagulants, when subdural haematomas were observed, they performed EBP, which resulted in dramatic recanalisation of thrombosed venous sinuses. Therefore, as SIH may be suggested as the underlying condition rather than a simple coexistence, we speculate that EBP should be applied and therapy for CVST should be started after maturation of EBP.

However, further studies and case reports are needed to determine optimal treatment.

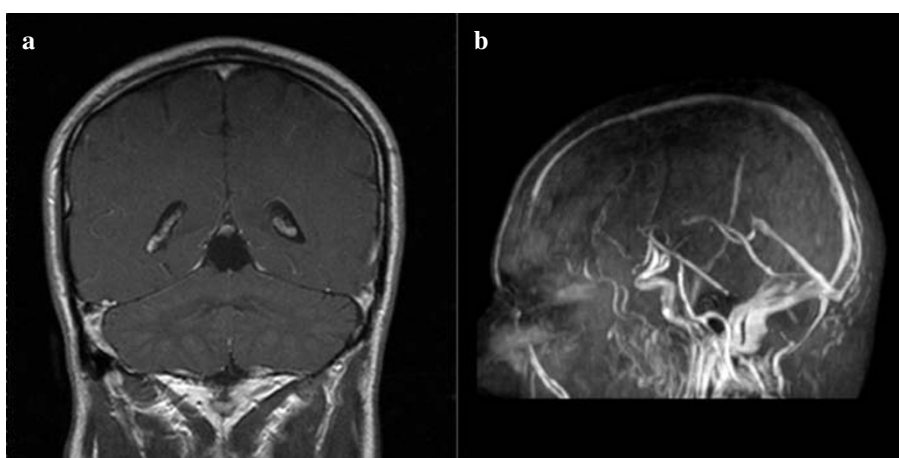
---

*Editor's note: Intrathecal MR cisternography is not allowed in European countries.*

---



**Fig. 1a-c** Before the treatment, the contrast-enhanced T1-weighted (a) image revealed dural thickening (arrows) and filling defect in the superior sagittal sinus (arrowhead). MR venography (b) shows superior sagittal sinus thrombosis (arrows). Intrathecal gadolinium (0.5 ml gadopentate dimeglumine)-enhanced MR cisternography (c) shows diffuse epidural collections over the lower dorsal area



**Fig. 2a, b** One month after treatment, contrast-enhanced T1-weighted (a) image reveals regression of dural thickening and MR venography (b) shows recanalisation of superior sagittal sinus thrombosis

## References

1. Merlo P, Clerici AM, Stival B et al (2005) Spontaneous intracranial hypotension: case report. *J Headache Pain* 6:477
2. Trappolini M, Clarice A, Scorza A et al (2006) A case of spontaneous intracranial hypotension with typical magnetic resonance images. *J Headache Pain* 7:44–46
3. Savoirdo M, Armenise S, Spagnolo P et al (2006) Dural sinus thrombosis in spontaneous intracranial hypotension: Hypotheses on possible mechanisms. *J Neurol* 253:1197–1202
4. Kataoka H, Tanizawa E, Ueno S (2007) Spontaneous intracranial hypotension is associated with a risk of venous sinus thrombosis and subdural hematoma. *Cerebrovasc Dis* 23:315–317
5. Berroir S, Grabli D, Heran F et al (2004) Cerebral sinus venous thrombosis in two patients with spontaneous intracranial hypotension. *Cerebrovasc Dis* 17:9–12