

William S. Anderson
Paul P. Wang
Daniele Rigamonti

Case of microarteriovenous malformation-induced trigeminal neuralgia treated with radiosurgery

Received: 10 May 2006
Accepted in revised form: 8 June 2006
Published online: 11 August 2006

W.S. Anderson
The Johns Hopkins University,
School of Medicine,
Department of Neurosurgery,
Meyer Building 8-161,
600 North Wolfe Street,
Baltimore, MD 21287, USA

P.P. Wang
The Johns Hopkins University,
School of Medicine,
Department of Neurosurgery,
Phipps Building, Room 101,
600 N. Wolfe Street,
Baltimore, MD 21287, USA

D. Rigamonti (✉)
The Johns Hopkins University,
School of Medicine,
Department of Neurosurgery,
Phipps Building, Room 104,
600 N. Wolfe Street,
Baltimore, MD 21287, USA
e-mail: dr@jhmi.edu
Tel.: +1-410-955-2259
Fax: +1-410-955-9126

Abstract Radiosurgery to the right fifth cranial nerve was performed with the Gamma Knife on a 39-year-old patient who presented with classic symptoms of trigeminal neuralgia (TN), but was found on imaging studies to harbour a small intrinsic vascular malformation within the nerve. Based on size and drainage, the arteriovenous malformation (AVM) was Spetzler-Martin Grade III and no previous history of bleeding was reported. The patient had failed a trial of carbamazepine, and no surgical procedures had been performed. A decrease in symptoms was reported by the 6-month follow-up. A review of the literature on microAVM-induced TN is provided as well as a discussion of management.

Key words Trigeminal neuralgia • Radiosurgery • Arteriovenous malformation • Gamma Knife • Cerebellopontine angle

Introduction

Trigeminal neuralgia (TN) has an approximate incidence of 5/100 000 and typically affects people in their 6th and 7th decades of life [1]. Common causes of the condition include multiple sclerosis and benign masses in the cere-

bellopontine angle (CPA) [2]. The majority (80%–90%) of TN cases are produced by vascular compression effects [2]. Of these cases, up to 80% are caused by compression from the superior cerebellar artery (SCA), with the next most likely cause coming from venous compression [3, 4].

There have been a few case reports from the past century reporting TN caused by arteriovenous malformations

(AVM) [5–8] of the posterior fossa as well as two short series of patients [9, 10] with AVMs involving the nerve itself. Johnson and Salmon [8] describe a 29-year-old patient who bled from a large posterior fossa AVM involving the right CPA, which was diagnosed only after the patient had undergone a series of intracranial nerve sectioning and ganglionectomy procedures. Tsubaki et al. [9] describe a series of seven patients, all presenting with typical TN symptoms, who were discovered upon surgery to harbour small AVM-like lesions with arterIALIZED petrosal veins and a tangle of vessels around the nerve root. None of these patients had clear solitary compression from either the SCA or the anterior inferior cerebellar artery (AICA). These patients underwent suboccipital craniectomy and resection of the AVM nidus could be performed in six of them. In four of the patients the nerve had to be sacrificed due to its complex involvement with the AVM [9].

The most recent large report is that of Edwards et al. [10], who describe in a series of 341 patients undergoing a suboccipital craniectomy the discovery in five patients of an AVM involving the trigeminal nerve. Only one of these cases demonstrated abnormal vasculature around the nerve on preop imaging. In this series the surgeons were able to resect the small AVMs while preserving the nerve. The predominant origin of the feeding vessels was the intrinsic pontine vasculature, with other sources being the SCA and the AICA. There was no evidence of previous haemorrhage intraoperatively in these cases. The patients were pain free after a mean follow-up of 30 months [10].

This report discusses the case of a small AVM involving the trigeminal nerve near the pons treated not by surgical resection, but by radiosurgery. We have found no other similar reports in the literature. There is a long history of radiosurgical treatment of AVMs of the brainstem [11, 12] as well as for TN [13, 14], in which case it is frequently used for the elderly patient or patients who cannot undergo invasive procedures. A description of this patient's presentation as well as the therapeutic decision is provided below.

Case report

The patient presented at the age of 39 with an approximate two-year history of lancinating episodic sharp pains originating on the right lateral surface of the nose, and radiating to the right midpupillary point under the eye. Initially these episodes lasted only for a few seconds and occurred only once or twice a day. The patient was at times symptom free for month-long periods. After the pains became more frequent, he was referred to an otolaryngologist and treatment for sinusitis was instituted to no avail. At this point his symptoms became even more frequent, and could be triggered by eating or talking. Two years into his disease, the patient was having episodic pain almost every 15 min during a bad day, but he would also have periods of 2–3 days with minimal problems. Acetaminophen/oxycodone (325 mg/10 mg) was used for pain control, having already been prescribed for arthritis. This dulled some aspects of the pain. The patient also underwent a wisdom tooth extraction at the two-year point, which did not affect his facial pain. The patient at that point was referred to a neurosurgeon and a radiation oncologist for treatment of presumed classic TN.

On examination, the patient demonstrated no sensory loss or altered sensation in the facial dermatomes. The rest of his neurological exam was nonfocal. In coordination with a neurologist a trial of carbamazepine was undertaken. This greatly decreased the frequency and intensity of his painful episodes, although over time it became less effective, even up to doses of 1500 mg/day. An MRI arranged by the neurologist revealed a pattern of flow voids consistent with an AVM in the right CPA (Fig. 1a). Subsequently, a four-vessel cerebral angiogram was obtained, which demonstrated an approximate 1.2x0.8x0.9 cm AVM, with primary feeding arteries coming from the pontine perforators as well as the SCA (Fig. 2). The AVM demonstrated a deep pattern of drainage via the right basal vein of Rose0nthal into the straight sinus. There was also

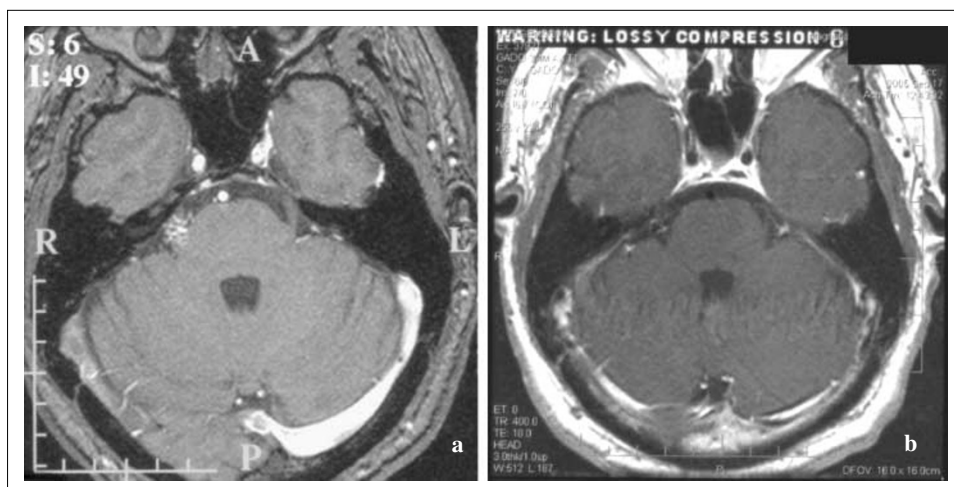


Fig. 1a MRA single slice source image through the cerebellopontine region demonstrates the abnormal vasculature in the right CP angle. **b** Post-treatment T1 axial MRI with gadolinium at the same level showing reduction in size of the lesion (nidus read at 0.8x0.4 cm on this slice)

some drainage into the right superior petrosal sinus. By the Spetzler-Martin scale [15], this was a Grade III AVM.

The patient had performed a significant amount of research on the pros and cons of both open surgical treatment and Gamma Knife therapy for TN and AVMs. After being presented with the options and risks, he chose to have the Gamma Knife treatment. He underwent stereotactic frame placement and stereotactic radiosurgery in one sitting. Repeat angiography was performed with the frame in place for localisation (Fig. 3). The target volume from the treatment plan was 896 mm³. The prescribed dose was 20.1 Gy to the 50% isodose line, and the conformity index based on the outlined target with comparison to the shot overlap was 1.37. The brainstem received an average dose of 3.5±2.7 Gy, with the right and left lenses both receiving on average 0.5±0.1 Gy. Dose to the chiasm was on average 1.4±0.1 Gy. The patient tolerated the procedure well and was discharged home on the same day. A six-month follow-up MRI revealed reduction in the volume of flow void abnormality (Fig. 1b). At 13 months of follow-

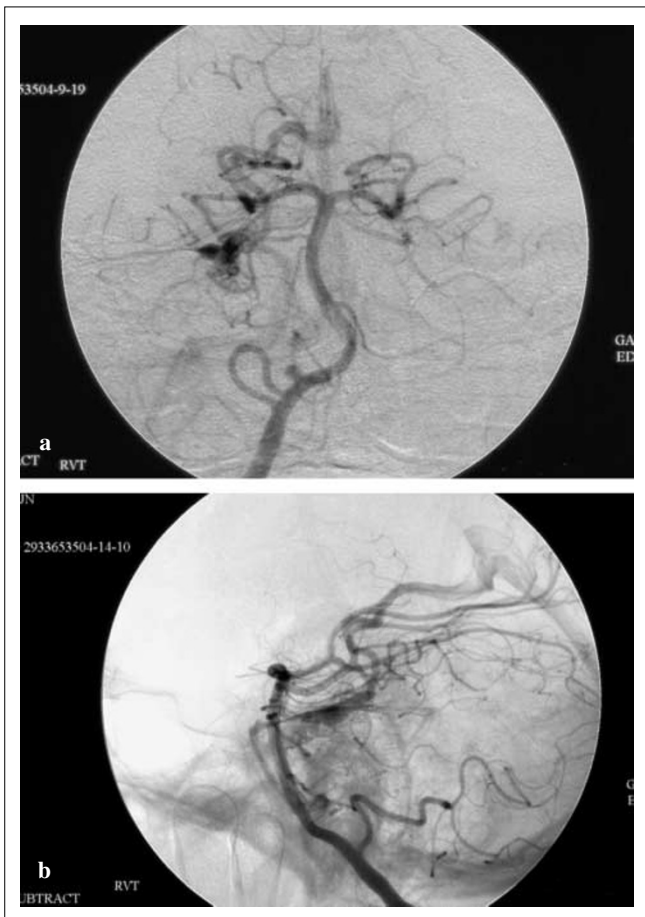


Fig. 2 Subtraction right vertebral angiography injections (**a** AP and **b** lateral) demonstrating the AVM fed by pontine perforators and the SCA

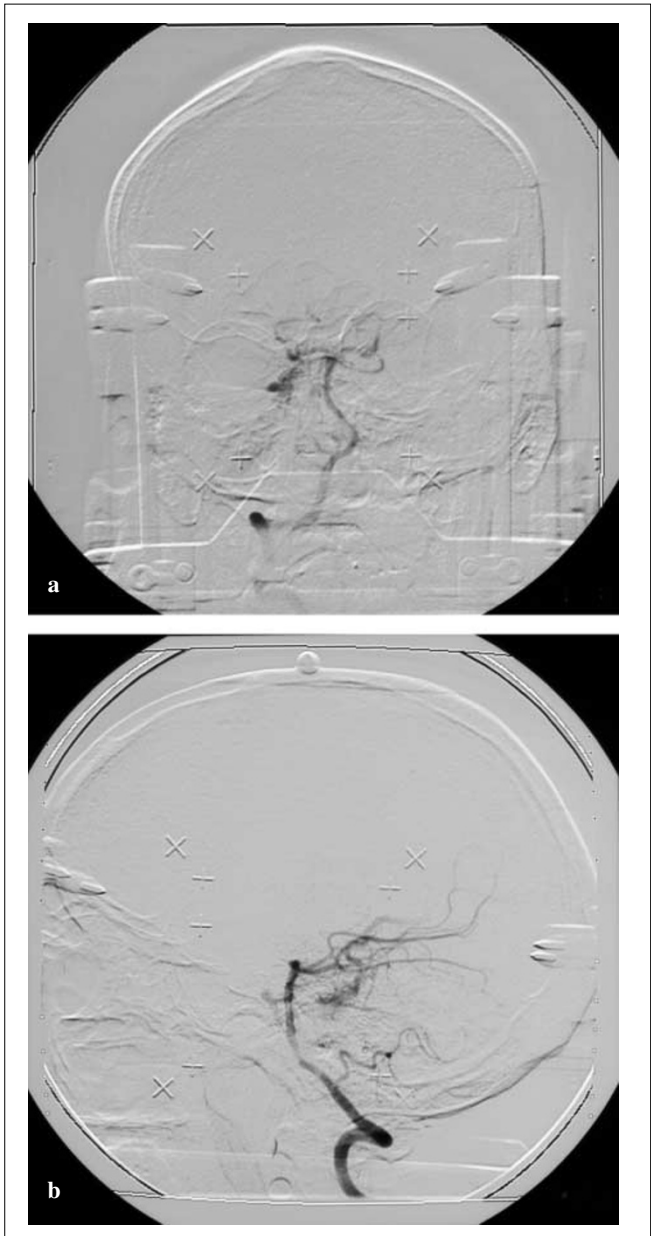


Fig. 3a AP and **b** lateral right vertebral artery injections taken with stereotactic frame in place

up, the patient was no longer having painful episodes and had stopped carbamazepine treatment.

Discussion

Over a 20-year time period, Edwards et al. [10] performed posterior fossa surgery on 341 patients with the symptoms of TN specifically for microvascular decompression of the fifth cranial nerve. Five of them were found to have a small

trigeminal nerve involving AVM (1.5%). Similarly, over a 9-year time period, 1257 patients were operated on by Tsubaki et al. [9] for TN, of whom 7 had a small AVM involving the fifth nerve and the pons (0.6%). These patients all presented with typical TN symptoms, and only rarely was the lesion discovered preoperatively. As far as the authors are aware, this is the first case report of an intrinsic trigeminal AVM that was treated solely with radiosurgery. A previous case report [16] describes a 55-year-old man with an intrinsic AVM who was initially treated with surgery. At the time of the operation however, the surgeons discovered an aberrant SCA loop impinging on the nerve at the region of the root entry zone. These authors displaced this vessel from the nerve root and then planned to treat the AVM later with radiosurgery, although this is so far unreported. In the two series of operative cases [9, 10], compression by the SCA or other arterial vessels was described as minor [10] or non-existent [9], supporting the causal role of the intrinsic AVM.

It is tempting to attribute the pathogenesis of TN in this patient to compressive effects from the tortuous vessels of the AVM, but unfortunately not much is known about intrinsic cranial nerve AVMs at the tissue level. In general, compression of the trigeminal nerve results in axonal loss and demyelination close to the region of compression, with an associated increase in astrocytic processes and the occurrence of a liposomal froth from residual myelin sheaths in neighbouring regions [17]. When pain relief does occur after a decompressive procedure, it is thought to be derived from a decrease in ectopic pulse generation derived from an increase in neighbour-to-neighbour spacing of the trigeminal nerve fibres [18]. The mechanism of action of radiosurgery in TN is less well understood, but may also involve a decrease in ephaptic conduction [13].

Our 39-year-old otherwise healthy patient was an excellent surgical candidate, and there were no compelling reasons not to offer this option to him. A multimodality approach as advocated by Lawton et al. [12] might have been necessary had the resection been incomplete. He was very interested in the possible treatment choices, and preferred after the discovery of his lesion to undergo Gamma Knife therapy, which he had already chosen for the treatment of his TN before any imaging studies had been performed.

Frame placement and treatment were tolerated well and no problems related to treatment were reported at the first follow-up visit.

The radiosurgical treatment of TN is accompanied by a significant recurrence of pain, with rates as high as 23% [13, 14]. Some patients are left with facial numbness (29%) or dysaesthesias (18%) [14]. Transient brain stem radiation effects have also been reported in a series of 30 patients treated with radiosurgery for brainstem AVMs [19], including ptosis, ataxia and eye movement disorders (all eventually resolving) after radiosurgery for midbrain AVMs. The onset of radiation problems can be delayed, occurring up to two years after treatment. Persistent deficits from radiation-induced edema have also been reported after radiosurgery for a pontine AVM [20].

Success rates for this form of treatment can be as high as 61% pain relief over long periods of follow-up when treating idiopathic TN [13, 14].

When counselling patients regarding treatment options for this type of condition, a discussion of the possibility of future haemorrhage from the AVM after radiosurgery must also be held. For brainstem AVMs, this obviously can be very dangerous, and annual post-treatment bleeding rates of 4% have been described [19]. Lower radiation doses used in some series (≤ 17 Gy), which implies longer obliteration times, have demonstrated more extended periods of bleeding risk including up to 8 years post-treatment [19]. The natural history of these lesions after radiosurgery seems to be very similar to untreated AVMs within the first 18 months for standard dose therapy, but the bleeding rate drops considerably after that [11]. Obliteration rates for this size range of AVM (mean 18 mm diameter) have been reported as $>80\%$ at the two-year follow-up [11].

In conclusion, we believe this case points out the importance of MRI evaluation during the work-up of patients with presumed TN. The use of MRI imaging to identify an offending compressive vessel loop and predict surgical outcome may be too premature [21]. However, higher resolution techniques and high field scanners are making more thorough evaluations possible [22], and certainly in this case, standard MRI imaging resulted in the discovery of the offending lesion.

References

1. Katusic S, Williams DB, Beard CM, Bergstrahl EJ, Kurland LT (1991) Epidemiology and clinical features of idiopathic trigeminal neuralgia and glossopharyngeal neuralgia: similarities and differences, Rochester, Minnesota, 1945–1984. *Neuroepidemiology* 10:276–281
2. Love S, Coakham HB (2001) Trigeminal neuralgia: pathology and pathogenesis. *Brain* 124:2347–2360
3. McLaughlin MR, Jannetta PJ, Clyde BL et al (1999) Microvascular decompression of cranial nerves: lessons learned after 4400 operations. *J Neurosurg* 90:1–8
4. Ishikawa M, Nishi S, Aoki T et al (2002) Operative findings in cases of trigeminal neuralgia without vascular compression: proposal of a different mechanism. *J Clin Neurosci* 9:200–204
5. Olivecrona H (1949) Cholesteatomas of the cerebello-pontine angle. *Acta Psychiatr Neurol Scand* 24:639–643

6. Eisenbrey AB, Hegarty WM (1956) Trigeminal neuralgia and arteriovenous aneurysm of the cerebellopontine angle. *J Neurosurg* 13:647–649
7. Verbiest H (1961) Arterio-venous aneurysms of the posterior fossa. Analysis of six cases. *Acta Neurochir* 9:171–195
8. Johnson MC, Salmon JH (1968) Arteriovenous malformation presenting as trigeminal neuralgia. *J Neurosurg* 29:287–289
9. Tsubaki S-I, Fukushima T, Tamagawa T et al (1989) Parapontine trigeminal cryptic angiomas presenting as trigeminal neuralgia. *J Neurosurg* 71:368–374
10. Edwards RJ, Clarke Y, Renowden SA, Coakham HB (2002) Trigeminal neuralgia caused by microarteriovenous malformations of the trigeminal nerve root entry zone: symptomatic relief following complete excision of the lesion with nerve root preservation. *J Neurosurg* 97:874–880
11. Duma CM, Lunsford LD, Kondziolka D et al (1993) Radiosurgery for vascular malformations of the brain stem. *Acta Neurochir* 58[Suppl]:92–97
12. Lawton MT, Hamilton MG, Spetzler RF (1995) Multimodality treatment of deep arteriovenous malformations: thalamus, basal ganglia, and brain stem. *Neurosurgery* 37:29–36
13. Kondziolka D, Lunsford LD, Flickinger JC (1998) Gamma knife radiosurgery as the first surgery for trigeminal neuralgia. *Stereo Funct Neurosurg* 70[Suppl 1]:187–191
14. McNatt SA, Yu C, Giannotta SL et al (2005) Gamma knife radiosurgery for trigeminal neuralgia. *Neurosurgery* 56:1295–1303
15. Spetzler RF, Martin NA (1986) A proposed grading system for arteriovenous malformations. *J Neurosurg* 65:476–483
16. Karibe H, Shirane R, Jokura H, Yoshimoto T (2004) Intrinsic arteriovenous malformation of the trigeminal nerve in a patient with trigeminal neuralgia: case report. *Neurosurgery* 55:1445–1449
17. De Ridder D, Møller A, Verlooy J, Cornelissen M, De Ridder L (2002) Is the root entry/exit zone important in microvascular compression syndromes? *Neurosurgery* 51:427–434
18. Love S, Coakham HB (2001) Trigeminal neuralgia: pathology and pathogenesis. *Brain* 124:2347–2360
19. Kurita H, Kawamoto, Sasaki T et al (2000) Results of radiosurgery for brain stem arteriovenous malformations. *J Neurol Neurosurg Psychiatry* 68:563–570
20. Yamamoto M, Jimbo M, Lindquist C (1992) Radiation-induced edema after radiosurgery for pontine arteriovenous malformation. *Surg Neurol* 37:15–21
21. Kress B, Schindler M, Rasche D et al (2006) Trigeminal neuralgia: how often are trigeminal nerve-vessel contacts found by MRI in normal volunteers. *Fortschr Rontgen Nuklearmed* 37:15–21
22. Anderson VC, Berryhill PC, Sandquist MA et al (2006) High-resolution three-dimensional magnetic resonance angiography and three-dimensional spoiled gradient-recalled imaging in the evaluation of neurovascular compression in patients with trigeminal neuralgia: a double-blind pilot study. *Neurosurg* 58:666–673