

RESEARCH ARTICLE

Open Access

# Cuneus and fusiform cortices thickness is reduced in trigeminal neuralgia

Maud Parise<sup>1,2\*</sup>, Tadeu Takao Almodovar Kubo<sup>1</sup>, Thomas Martin Doring<sup>1</sup>, Gustavo Tukamoto<sup>1</sup>, Maurice Vincent<sup>1,3</sup> and Emerson Leandro Gasparetto<sup>1</sup>

## Abstract

**Background:** Chronic pain disorders are presumed to induce changes in brain grey and white matters. Few studies have focused CNS alterations in trigeminal neuralgia (TN).

**Methods:** The aim of this study was to explore changes in white matter microstructure in TN subjects using diffusion tensor images (DTI) with tract-based spatial statistics (TBSS); and cortical thickness changes with surface based morphometry. Twenty-four patients with classical TN (37-67 y-o) and 24 healthy controls, matched for age and sex, were included in the study.

**Results:** Comparing patients with controls, no diffusivity abnormalities of brain white matter were detected. However, a significant reduction in cortical thickness was observed at the left cuneus and left fusiform cortex in the patients group. The thickness of the fusiform cortex correlated negatively with the carbamazepine dose ( $p = 0.023$ ).

**Conclusions:** Since the cuneus and the fusiform gyrus have been related to the multisensory integration area and cognitive processing, as well as the retrieval of shock perception conveyed by A $\delta$  fibers, our results support the role of these areas in TN pathogenesis. Whether such changes occurs as an epiphenomenon secondary to daily stimulation or represent a structural predisposition to TN in the light of peripheral vascular compression is a matter of future studies.

**Keywords:** Trigeminal neuralgia; MRI; Brain; Cortical thickness analysis; White matter; Diffusion tensor imaging

## Background

Classical trigeminal neuralgia (TN) is characterized by severe paroxysms of electric, shock-like pain limited to one or more divisions of the trigeminal nerve [1]. It is commonly evoked by trivial stimuli but frequently occurs spontaneously.

Although TN's pathogenesis is not fully understood, there is increasing evidence suggesting that it may be related to chronic vascular compression of the trigeminal nerve root entry zone (REZ). This chronic compression may lead to focal demyelination, consequent generation of aberrant activities (ectopic discharges) and pathological

cross-activation between large and small afferent fibers (ephaptic cross-talk) [2]. This peripheral process may induce secondary central changes resulting in sensitization of nociceptive neurons at the trigeminal nucleus and/or higher brain structures [3,4].

Abnormal high-frequency stimulation due to chronic pain could likewise induce morphological changes in nociception modulatory areas. Grey matter abnormalities have been observed in several chronic painful conditions like phantom pain, chronic back pain, fibromyalgia and chronic head pain [5-7]. On the other hand, white matter diffusional changes were reported in brain areas involved in sensory, modulatory and cognitive functions in temporomandibular disorder (TMD), cluster headache, migraine, complex regional pain syndrome CRPS and fibromyalgia [8-12].

Two previous publications reported on reduction of grey matter volume (GMV) in TN using voxel-based morphometry (VBM) in brain areas related to pain

\* Correspondence: parise@infolink.com.br

<sup>1</sup>Department of Radiology, Clementino Fraga Filho University Hospital, Universidade Federal do Rio de Janeiro, Rua Rodolpho Paulo Rocco, 255, Cidade Universitária, Rio de Janeiro, CEP:21941-913, Brazil

<sup>2</sup>Department of Surgical Specialties, Division of Neurosurgery Pedro Ernesto University Hospital, Universidade do Estado do Rio de Janeiro, Boulevard Vinte e Oito de Setembro, 77 Vila Isabel, Rio de Janeiro, RJ CEP: 20551-900, Brazil

Full list of author information is available at the end of the article

processing and integration [13,14]. The question remains as whether these results reflect plastic changes of the brain as a consequence of chronic nociceptive input or a causal factor for the development of TN.

The aim of this study was to investigate grey (GM) and white matter (WM) structural changes in TN and verify whether such changes would relate to disease duration, medication or sensory deficits. A MRI surface-based analysis was performed to approach GM abnormalities. For assessment of WM architectural diffusion tensor imaging (DTI) with fractional anisotropy (FA) measurements and tract-based-spatial-statistics (TBSS) were used.

## Methods

### Subjects

Twenty-four consecutive patients with classical TN (18 women, 6 men) according to the International Classification of Headache Disorders version III criteria [1] were prospectively evaluated between May 2009 and May 2012 at Pedro Ernesto University Hospital. The mean age was  $55.8 \pm 8.5$  years. Patients with symptomatic TN, other headache disorders, chronic pain elsewhere, diabetes mellitus, claustrophobia, psychiatric conditions, or previous TN operations were excluded. TN was located within the maxillary and/or mandibular branch of trigeminal nerve (V2-V3) in all but one patient, in which ophthalmic branch was also involved. TN affected the left and right sides in respectively 13 and 11 patients. The disease duration ranged from 1 to 17 years. Due to ethical reasons and to prevent head movements during scans, TN preventive medications were not discontinued.

Twenty-four matched healthy controls (12 women, 6 men, mean age  $56.3 \pm 7.8$  years) were also included. Clinical neurological examination was unremarkable in the control group. This study was conducted in accordance with the Declaration of Helsinki and was approved by the ethical committee of Clementino Fraga Filho University Hospital (Study 062/09). All patients and controls gave written informed consent for the participation in the study.

### Measurement of tactile and pain perception thresholds

Sensory and pain perception thresholds were obtained by using bipolar electrical stimulation with surface electrodes placed on the forehead above the eyebrow (V1); on the cheek (V2) and on the chin (V3) just lateral to the mental foramen. Constant-current square-wave electrical stimuli were delivered at a 3 Hz stimulation rate with 200 ms pulse duration and varying intensity (Medelec stimulator - Vickers Medical- UK). The patient was asked to state when stimuli of increasing current intensity became noticeable (detection threshold) and "definitely" painful (pain threshold). Thresholds were measured in all trigeminal divisions and compared to the opposite side. Threshold

values were determined by the method of limits, i.e. the average from five or more successive observations.

### Imaging parameters

All subjects underwent scanning in a 1.5 T MRI system (Avanto, Siemens Medical System, Erlangen, Germany) fitted with an 8-channel phased-array head coil, the following sequences of the brain obtained: 1) T1-weight 3D high-resolution magnetization-prepared rapid acquisitions with gradient echoes (3D-MPRAGE) sequence (128 slices;  $1 \times 1 \times 1.3$  mm<sup>3</sup> voxels;  $256 \times 256$  matrix size; field of view = 256 mm; echo time = 3.39 ms; repetition time = 2.530 ms; flip angle 7°; 1.3 mm thick slices). 2) Echo-planar diffusion-weighted images, with bipolar diffusion gradients in 30 orthogonal directions ( $122 \times 122$  matrix size, field of view = 256, repetition time = 10.1 s, echo-time = 94 ms, slices = 73, slice thickness = 2 mm, interslice gap = 0). To optimize the measurement of diffusion in the brain, only two b values were used ( $b_0 = 0$ ;  $b_1 = 900$  s/mm<sup>2</sup>).

To minimize motion artifacts the head of the subjects were fixed in the head coil. All images were investigated to be free of motion or ghosting.

### DTI analysis

For voxelwise diffusion modeling, diffusion data were analyzed using FMRIB's Diffusion Toolbox within FSL 4.1 (<http://www.fmrib.ox.ac.uk/fsl>) [15]. After performing eddy current correction and brain extraction, FA images for all subjects were created by fitting a tensor model to the raw diffusion data. Voxelwise statistical analysis of the FA data was carried out using TBSS (Tract-Based Spatial Statistics) [16], part of FSL. All subjects' FA data were aligned into a common space using the nonlinear registration tool FNIRT, which uses a b-spline representation of the registration warp field [17]. The FMRIB58\_FA standard-space template was used as the target in TBSS ([http://www.fmrib.ox.ac.uk/fsl/data/FMRIB58\\_FA.html](http://www.fmrib.ox.ac.uk/fsl/data/FMRIB58_FA.html)). Next, the mean FA image was created and thinned to create a mean FA skeleton, which represents the centers of all tracts common to the group. Each subject's aligned FA data were then projected onto this skeleton, and the resulting data were fed into voxelwise cross-subject statistics for all voxels with  $FA \geq 0.30$  to exclude peripheral tracts with significant inter-subject variability. The voxelwise analysis was performed using permutation-based inference (5000 permutations) corrected for multiple comparisons, with a threshold-free cluster enhancement (TFCE) and significance level of  $p < 0.05$ . Corrected TFCE p-value images were computed to enable the identification of differences in the FA areas between patients and healthy control subjects. The WM tracts were then identified using the Johns Hopkins University white matter tractography atlas and the International

Consortium for Brain Mapping DTI-81 white matter labels atlas, both of which are available within FSL.

#### **Subcortical volumetry and cortical thickness analysis**

Automatic subcortical volumetric segmentation and cortical thickness evaluation was performed using the FreeSurfer® (FS) image analysis suite (v.5.0.0 Martinos Center for Biomedical Imaging, Harvard-MIT, Boston, MA), which is documented and freely available for download (<http://surfer.nmr.mgh.harvard.edu/>). The technical details of these procedures were described previously [18]. Briefly, this fully automated process includes motion correction, removal of non-brain tissue, automated Talairach transformation, segmentation of the subcortical white matter and deep grey-matter volumetric structures (including hippocampus, amygdala, caudate, putamen, and ventricles), intensity normalization, and cortical reconstruction. This segmentation procedure assigns a neuro-anatomical label to every voxel in the MR image volume. The method is based on probabilistic information estimated from a manually labeled training set. The Markov random field theory is applied, where the probability of a label at a given voxel is computed not just in terms of the grey-scale intensities and prior probabilities at that voxel, but also as a function of the labels in a neighborhood around the voxel in question. This is important for correct differentiation between the hippocampus and amygdala, which have similar grey-scale values. The results of the automatic segmentations were reviewed and any errors were corrected. Correction for the intracranial volume (ICV), including white matter, grey matter, and cerebrospinal fluid, was also estimated for each subject using FS. Individuals with a large intracranial volume tend to have larger subcortical structures; therefore, correction by the intracranial volume is crucial in volume quantification of the subcortical structures. This correction can be simply done by dividing numerically the volume of the subcortical structure through the ICV.

Cortical thickness maps were calculated for each subject. The mean cortical thickness in regions-of-interest in the groups were computed and statistically compared ( $p < 0.01$ ) by a single-binary application included in the FreeSurfer distribution, Qdec (Query, design, estimate, contrast). Correction for multiple comparisons was made by Qdec using Monte-Carlo simulation ( $p = 0.05$ ). Procedures for the accuracy of cortical thickness measurements have been validated with histological analysis [19] and manual measurements [20].

#### **Statistical analysis**

Demographic characteristics, perception thresholds and subcortical volumetry data were compared using the non-parametric Mann-Whitney U-test. Student T-test was used to compare threshold values in each trigeminal

division in the affected side with the unaffected side. Pearson correlation coefficients were used to evaluate whether the GM/WM changes correlated with disease duration, carbamazepine doses, sensory and pain perception thresholds. SPSS 13.0 (SPSS, Chicago IL, USA) was used for data analysis. Data shown as mean  $\pm$  SD. The level of significance was set at  $p < 0.05$ .

## **Results**

#### **Patient demographics**

Patients demographics are shown in Table 1. Patients and control groups did not differ in age (patients:  $55.8 \pm 8.5$  years; controls:  $56.3 \pm 7.8$  years;  $p = 0.88$ ). All patients scored TN paroxysms as 10 in a visual analog pain scale and remained pain free between the attacks. A 200-1800 mg/day Carbamazepine (CBZ) regimen was used by all subjects except two. There was a strong positive correlation between the CBZ dose and the disease duration TN ( $r = 0.489$ ,  $p = 0.015$ ).

#### **Tactile and pain perception thresholds**

The tactile perception thresholds were  $5.03 \pm 0.9$  and  $4.9 \pm 0.7$  mA on the symptomatic and non-symptomatic sides respectively ( $p = 0.94$ ). The pain perception thresholds were accordingly  $12.1 \pm 2.1$  and  $12.1 \pm 1.9$  mA ( $p = 0.78$ ). There was no difference between tactile perception thresholds in patients ( $5.03 \pm 0.8$  mA) and controls ( $4.9 \pm 0.7$  mA)  $p = 0.61$ . However, the pain perception threshold was significantly higher bilaterally (symptomatic and non-symptomatic sides), in patients ( $12.3 \pm 2.1$  mA vs.  $10.7 \pm 2.1$  mA,  $p < 0.001$  - Figure 1). There was no significant correlation between the pain perception threshold and the carbamazepine dose ( $p = 0.11$ ).

#### **White matter results**

TBSS analysis revealed no significant differences in WM skeleton FA values between TN and healthy controls.

#### **Subcortical volumetry**

Compared with controls, TN patients had significant volumetric reduction of mid-anterior portion of corpus callosum ( $p = 0.04$ ). This reduction was not correlated with duration of disease or carbamazepine dose. There was no significant difference in thalamus volumetry between TN patients and controls or between the ipsilateral and contralateral thalamus in the patients group.

#### **Cortical thickness analysis**

According to a single-binary application analysis ( $p < 0.01$ ) TN patients presented increased cortical thickness in some areas including sensory, premotor, prefrontal, middle temporal cortex and cingulate gyrus; and decrease in others, such as the motor, insular, orbito-frontal, cuneus/precuneus and inferior temporal/fusiform cortices (Figure 2).

**Table 1 Characteristics of TN patients**

Patient	Gender	Age (years)	TN duration (years)	Pain distribution	Side	CBZ dose (mg/day)
1	M	65	2	V2	R	1200
2	F	65	5	V2 + V1	L	200
3	F	40	4	V2	R	1000
4	F	62	8	V2 + V3	L	400
5	F	65	9	V2 + V3	L	800
5	F	53	4	V2 + V3	R	200
7	F	64	10	V3	L	800
8	F	62	5	V2	L	800
9	F	52	12	V3	R	1000
10	M	54	4	V2	R	400
11	F	57	11	V2 + V3	L	1800
12	F	48	5	V2	R	0
13	F	62	10	V2	R	800
14	F	53	10	V2 + V3	R	800
15	F	53	1	V3	L	0
16	M	49	9	V2	R	1800
17	F	62	17	V2 + V3	L	800
18	M	40	5	V3	L	800
19	M	53	6	V2 + V3	R	1200
20	M	37	5	V2	L	400
21	F	56	12	V2 + V3	L	800
22	F	67	6	V2	L	600
23	F	61	1	V2	R	200
24	F	61	10	V2	L	1200

TN = trigeminal neuralgia; F = female; M = male; R = right; L = left; V1 = ophthalmic branch; V2 = maxillary branch; V3 = mandibular branch; CBZ = carbamazepine.

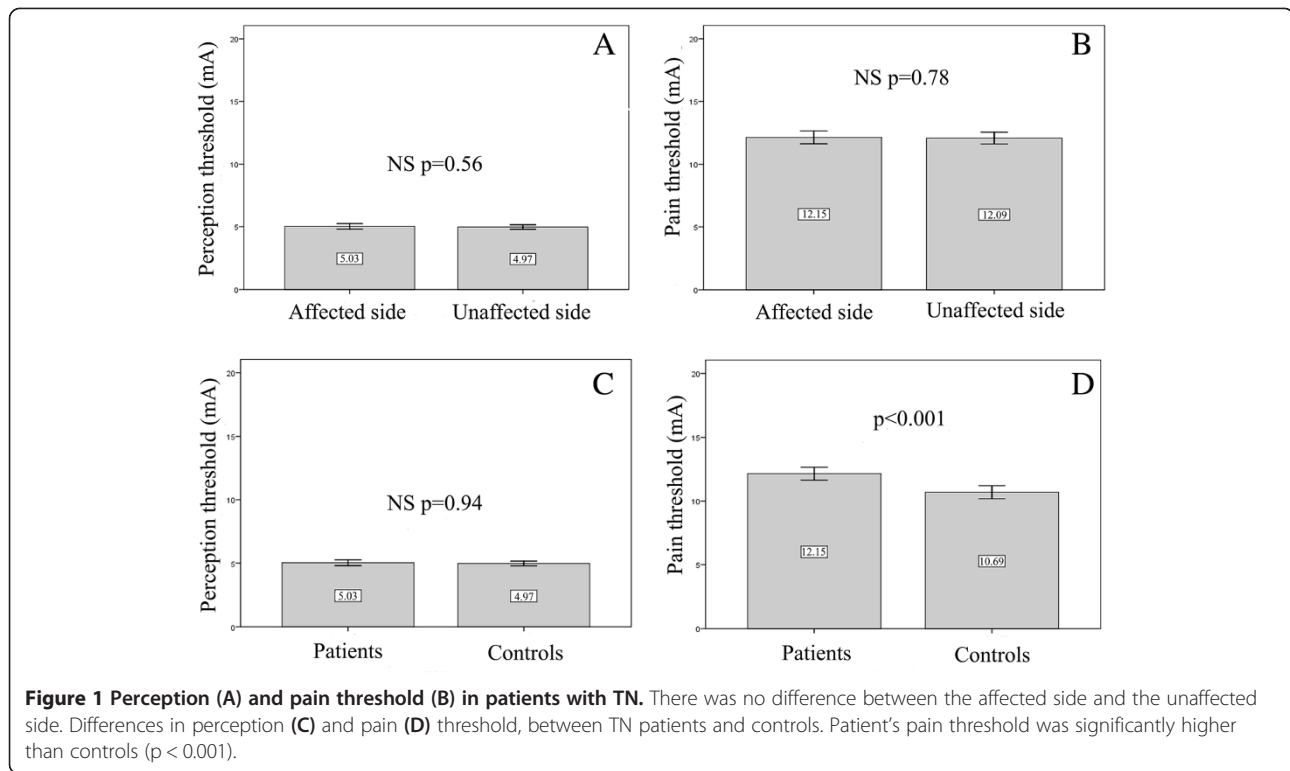
After correction for multiple comparisons, only the inferior temporal/fusiform cortex and cuneus/precuneus areas remained significantly thinner ( $p = 0,05$ ) (Figure 3). Cortical thickness at these areas correlated neither with disease duration nor with tactile and pain perception thresholds. However, a significant negative correlation between fusiform cortex thickness and carbamazepine dose was noticed ( $r = - 0.463$ ,  $p = 0.023$ ).

Four patients re-examined 6 months after successful microvascular decompression showed no significant difference between the pre- and postoperative findings.

## Discussion

Although the sensory function is roughly normal in patients with TN, subtle tactile and thermal sensory deficits may occur at the trigeminal territory as detected by sophisticated quantitative sensory testing [21]. A delayed conduction in large afferent fibres has been detected in 50% of TN patients even in the absence of any clinical hypoesthesia [22]. A conduction delay and a nociceptive laser-evoked potential amplitude reduction have been

demonstrated ipsilaterally in 51% of TN subjects [23], indicating a dysfunction in A $\delta$  and C fibres. The present study sought to detect these trifling changes - expectantly reflecting axonal lesions, demyelination and/or conduction block - as assessed by tactile and painful threshold in order to correlate them with possible WM diffusional and GM morphological changes. No significant differences in tactile and pain thresholds between the symptomatic and non-symptomatic sides or in tactile threshold between patients and controls were noticed. However, the pain threshold in patients was slightly and significantly increased ( $p \leq 0.001$ ). Bilateral activation of the descending diffuse noxious inhibitory controls (DNIC) with release of endorphins, due to the repetition of painful paroxysms of TN [24] could explain this finding, but this seems unlikely since during pain threshold determination no neuralgic pain putatively activating the inhibitory control has been triggered. A second possibility would be the antinociceptive effect of CBZ, which has been described in rats [25,26] and TN patients after noxious laser stimulation [23].



### TN and white matter abnormalities

The results of this investigation suggest that the brain white matter tracts microstructure is spared in TN, as shown by the absence of DTI abnormalities.

Subtle abnormalities revealed by FA decrease have been detected in the trigemino-thalamic and thalamocortical tracts in migraine patients [10]. Subsequent studies using TBSS analysis in other pain conditions (fibromyalgia [12], complex regional pain [11], cluster headache [9], temporomandibular disorders [8]) have reported abnormalities in white matter tracts involved in sensory, modulatory and cognitive functions.

The present results could be interpreted in two different ways. First, changes in diffusion could be too subtle or restricted to be identified by TBSS analysis. The sample size seems adequate as abnormalities have been detected in about seven cluster headache patients using the same technique [9]. Second, there are really no changes in diffusion in TN differently to migraine. Perhaps because TN is a paroxysmal pain, unlike the complex regional pain, TDM or fibromyalgia and/or does not involve in principle a genetic predisposition as in migraine. It seems that the diffusional abnormalities in the trigeminal root on the symptomatic side which would correspond to a focal demyelination and/or axonal loss [27] have no impact in the intracranial white matter tracts.

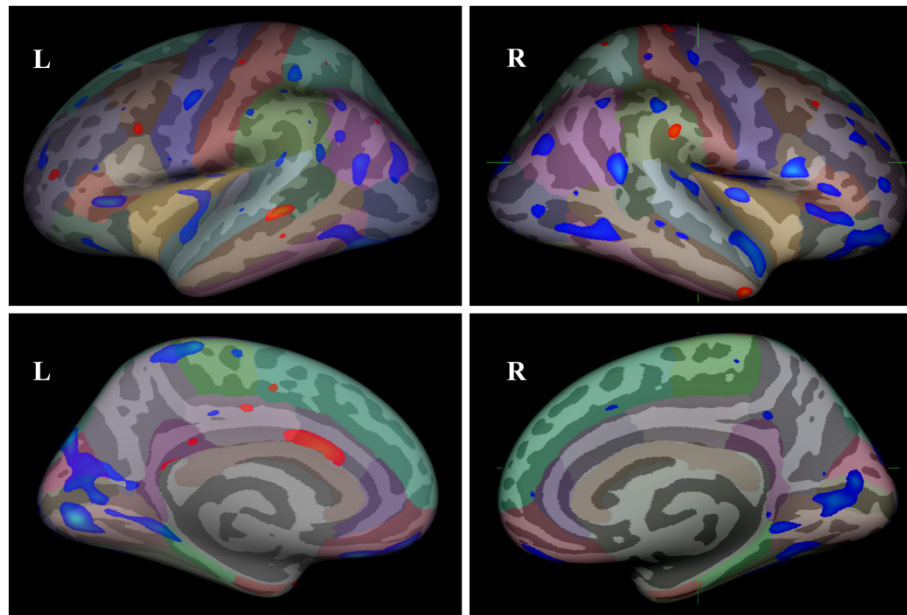
Nevertheless, we found a significant volume reduction ( $p = 0.04$ ) of the mid-anterior corpus callosum that

connects the motor areas of hemispheres. Clinical and experimental studies suggest an inhibitory effect of pain on the motor cortex [28-30]. Da Silva reported on reduced thickness of the primary motor cortex contralaterally to a trigeminal neuropathic pain, which could be hypothetically explained by inhibition of facial and cervical muscles to avoid pain triggering [31]. As patients with TN also limit talking, chewing and facial movements to avoid pain triggering [32,33], this could be also justify our findings.

### TN and grey matter abnormalities

We found changes in cortical thickness in TN patients as compared with controls. Cortical thickness changes, either increase or reduction, involve supraspinal nociceptive processing areas, such the orbitofrontal cortex, the insula and motor cortex, the anterior cingulate gyrus and temporal lobe, similarly to the other in pain syndromes. However, after the correction for multiple comparisons only the inferior temporal/fusiform cortex and cuneus/pre-cuneus regions remained significantly thinner ( $p = 0,05$ ). In addition, the inferior temporal gyrus/fusiform cortex thickness showed a negative correlation with CBZ dose, the larger the cortical thickness, the lower the medication usage.

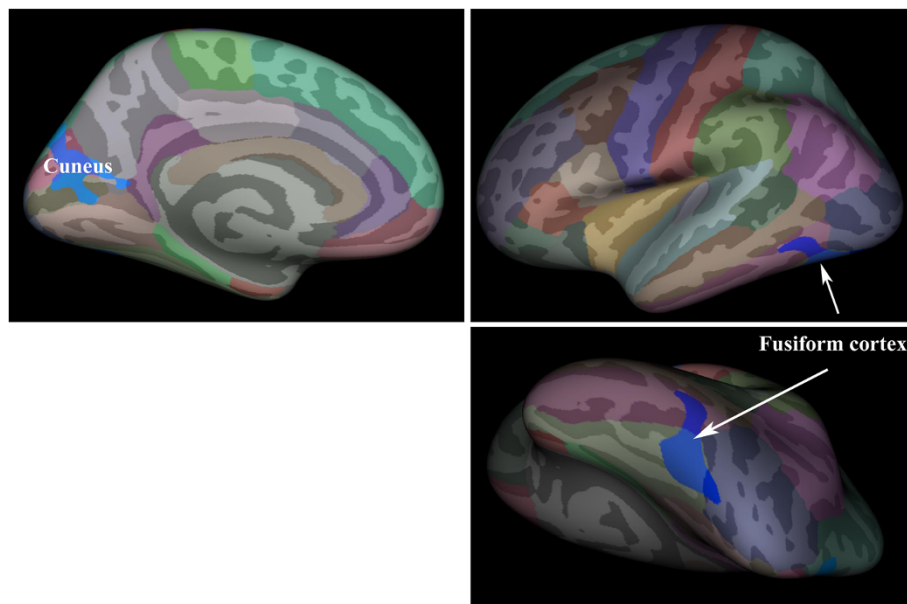
Pain-related grey matter changes have been reported in several pain conditions. A meta-analysis of 30 published VBM studies in 15 chronic pain conditions has shown that cortical changes (increase or decrease of grey



**Figure 2 Group differences in cortical thickness between TN patients and controls.** Blue regions indicate areas showing thickness reduction and red regions indicate thickness increase in TN patients when compared to controls at a threshold  $p < 0,01$ , uncorrected. It was observed cortical thickness changes in areas that include orbitofrontal cortex, insula, motor cortex, anterior cingulate gyrus and temporal lobe. All these regions, involved in supraspinal nociceptive processing, show grey matter alterations in different types of chronic pain.

matter) vary among different pain syndromes but overlap in areas such as cingulate and insular cortex, temporal lobe, frontal and prefrontal cortex, thalamus and basal ganglia, motor cortex, brainstem and dorsolateral prefrontal cortex, all brain areas involved in supraspinal

nociceptive processing [34]. In an heterogeneous group including both TN and trigeminal neuropathy, Gustin et al. [13] found grey matter reduction in the primary somatosensory cortex, anterior insula, putamen and nucleus accumbens. The thalamic volume decrease was only



**Figure 3 Group differences in cortical thickness between patients and controls after correction for multiple comparisons.** The inferior temporal gyrus (fusiform cortex) and cuneus/pre-cuneus showed significant thickness reduction (blue areas) in TN patients. The thickness reduction of fusiform cortex was negatively correlated to carbamazepine doses ( $p = 0.023$  rho 1.000 -0.463).

seen in patients with trigeminal neuropathy but not TN. An specific study of morphometric changes in TN [14] revealed brain matter volume reduction in the primary somatosensory and orbitofrontal cortices as well as anterior cingulate, cortex insula, secondary somatosensory cortex, thalamus, putamen, caudate nucleus, dorsolateral prefrontal cortex, precuneus and cerebellum. With these results Oberman et al. [14] concluded that the GMV reduction areas were nonspecific and would reflect only the chronic pain.

Our results are similar to the previous studies in pain syndromes only in a single-binary comparison ( $p < 0.01$ ), which could be explained by a lack of statistical power in this group of patients or most likely by methodological differences. Surface-based analyses provides a more precise measure of cortical thickness as VBM analysis reflects a mixed measure of grey matter, including cortical surface area or cortical folding, as well as cortical thickness [35].

After multiple comparisons only cuneus/precuneus and inferior temporal/fusiform cortex remained significantly thinner in the TN group. Although cuneus and precuneus areas are classically related to visual information processing, they are limited by the parieto-occipital sulcus, a multi-sensory integration area [36]. One of the cuneus function seems to be to integrate the somato-sensory information with other sensory stimuli and cognitive processes such as attention, learning and memory [37]. These areas are activated together with sensory/motor areas and structures related to pain in response to pricking sensation generated by a thermal painful stimulus in trigeminal and extra-trigeminal territory [38,39] and after selective stimulation of A $\delta$  fibers [40]. An EEG-MEG study in neurogenic pain patients showed precuneus and cuneus hyperactivation in patients with TN but not with lower limb pain [41]. In line with the present study, Oberman et al. [14] found a reduction in GMV in the left precuneus in TN patients not related to the pain duration, attack frequency or VRS. On the contrary, cluster headache patients have an increase in the cuneus GMV [42]. Pain is very intense in both TN and cluster headache, indicating that the opposite results in this respect cannot be explained by differences in pain severity. The pain location, mostly to the lower face in TN as opposed to retro-ocular, fronto-temporal areas in cluster headache; together with the clear pathophysiological differences, central/hypothalamic centered in cluster headache versus peripheral in TN, could explain the contrast in GMV findings among these disorders.

A significant reduction in cortical thickness was noticed in the left fusiform cortex, an area involved with body and face recognition [43]. It is also activated during postoperative pain [44] and by stimulation of A $\delta$  fibers as well as the cuneus [40].

The perception of painful electrical shock seems activate a number of cerebral areas, namely left fusiform

cortex, hippocampus, primary and associative visual cortex extending to the cuneus and precuneus as well as a more anterior network all belonging to dopaminergic pathways [45]. The activity of this areas was negatively correlated to pain intensity rating, especially at the left fusiform gyrus [45]. This posterior network, activated during electric shock stimulation, may be involved in a mental imagery process related to the retrieval of shock perception [45]. The pain in TN is shock-like in nature and could activate similar regions.

Volumetric changes of the left fusiform gyrus have been found in patients with migraine. Compared to controls, this region was significantly atrophied in migraine without aura, while in migraine with aura it was increased. In the most of patients the migraine was bilateral [46]. Pain anticipation and perception have been associated with the left fusiform gyrus, where the activity was negatively correlated with the pain rating [45]. It is possible that the left fusiform cortex reduction may not depend on the side where the pain occurs.

The role of CBZ on the present results cannot be overlooked as the inferior temporal/fusiform cortex thickness reduction was negatively correlated with the CBZ dose, which had a positive correlation with the illness duration. Chronic CBZ was shown to change cellular signaling in rats, which could interfere with the functional and structural responses of various brain areas [47]. It remains to be determined whether CBZ affects grey matter thickness or not.

The cornerstone of TN is the electric shock-like pain evoked at trigger zones by light touch. It seems related to the ephaptic cross-talk between A $\beta$  fibres mediating light touch and small-myelinated A $\delta$  fibres close to the trigeminal nerve root entry zone, where there a focal demyelination is caused by neurovascular compression. Our study showed a thickness reduction of the fusiform cortex and cuneus, structures that can be activated by A $\delta$  fibres stimulation and would be involved in a mental imagery process related to the retrieval of shock. These data strongly suggest that such cortical areas are involved in TN pathogenesis. However, our results do not elucidate whether these changes reflect plastic changes of the brain as a consequence of multiple, daily shock-like pain conveyed by A $\delta$  fibres or a causal factor in the development of TN. Although a partial reversal of morphologic changes of the brain after pain treatment has been reported Rodriguez-Raecke [48], the four patients re-scanned 6 months after successful microvascular decompression showed no evolutive changes. It is possible that either the follow-up was too short or TN actually requires an interplay between peripheral vascular compression and GM structural predisposition in order to develop, which is supported by the occasional presence of asymptomatic neurovascular compressions. Future studies may address this issue with longer follow-up.

## Conclusions

The present study provides evidence for GM abnormalities in areas usually involved with several chronic painful conditions, but also in specific areas as the cuneus and fusiform cortex, which may be related to retrieval of shock perception conveyed by A $\delta$  fibers in TN. No white matter microstructure changes were identified in TN.

## Abbreviations

TN: Trigeminal neuralgia; REZ: Root entry zone; TMD: Temporomandibular disorder; CRPS: Complex regional pain syndrome; GMV: Grey matter volume; VBM: Voxel-based morphometry; GM: Grey matter; WM: White matter; MRI: Magnetic resonance image; DTI: Diffusion tensor imaging; TBSS: Tract-based-spatial-statistics; V1: Ophthalmic branch; V2: Maxillary branch; V3: Mandibular branch; MPRAGE: Magnetization-prepared rapid acquisitions with gradient echoes; FA: Fractional anisotropy; TBSS: Tract-based-spatial-statistics; TFCE: Threshold-free cluster enhancement; FS: FreeSurfer; ICV: Intracranial volume; CBZ: Carbamazepine; VRS: Visual rate scale.

## Competing interests

None of the authors have received financial support for the generation of this article. The authors have no personal or institutional interest in any of the drugs, materials or devices described in this article.

## Authors' contributions

Conception, design of the work, interpretation of data and draft the article were done by: MP, EG and MV. Acquisition and analysis of data were done by: TK, TD and GT. All the authors have read and approved the paper.

## Author details

<sup>1</sup>Department of Radiology, Clementino Fraga Filho University Hospital, Universidade Federal do Rio de Janeiro, Rua Rodolpho Paulo Rocco, 255, Cidade Universitária, Rio de Janeiro, CEP:21941-913, Brazil. <sup>2</sup>Department of Surgical Specialties, Division of Neurosurgery Pedro Ernesto University Hospital, Universidade do Estado do Rio de Janeiro, Boulevard Vinte e Oito de Setembro, 77 Vila Isabel, Rio de Janeiro, RJ CEP: 20551-900, Brazil. <sup>3</sup>Department of Neurology, Clementino Fraga Filho University Hospital, Universidade Federal do Rio de Janeiro, Rua Rodolpho Paulo Rocco, 255, Cidade Universitária, Rio de Janeiro, CEP:21941-913, Brazil.

Received: 13 February 2014 Accepted: 12 March 2014

Published: 24 March 2014

## References

1. ICHD-III (2013) The International classification of headache disorders: 3rd edition (beta version). *Cephalalgia* 33:629–808, doi:10.1177/0333102413485658
2. Love S, Coakham HB (2001) Trigeminal neuralgia: pathology and pathogenesis. *Brain* 124:2347–2360
3. Moisset X, Villain N, Ducreux D, Serrie A, Cunin G, Valade D, Calvino B, Bouhassira D (2011) Functional brain imaging of trigeminal neuralgia. *Eur J Pain* 15:124–131
4. Obermann M, Yoon MS, Ese D, Maschke M, Kaube H, Diener HC, Katsarava Z (2007) Impaired trigeminal nociceptive processing in patients with trigeminal neuralgia. *Neurology* 69:835–841
5. Apkarian AV, Sosa Y, Sonty S, Levy RM, Harden RN, Parrish TB, Gitelman DR (2004) Chronic back pain is associated with decreased prefrontal and thalamic gray matter density. *J Neurosci* 24:10410–10415
6. Kuchinad A, Schweinhardt P, Seminowicz DA, Wood PB, Chizh BA, Bushnell MC (2007) Accelerated brain gray matter loss in fibromyalgia patients: premature aging of the brain? *J Neurosci* 27:4004–4007
7. May A (2008) Chronic pain may change the structure of the brain. *Pain* 137:7–15
8. Moayeddi M, Weissman-Fogel I, Salomons TV, Crawley AP, Goldberg MB, Freeman BV, Tenenbaum HC, Davis KD (2012) White matter brain and trigeminal nerve abnormalities in temporomandibular disorder. *Pain* 153:1467–1477
9. Teepker M, Menzler K, Belke M, Heverhagen JT, Voelker M, Mylius V, Oertel WH, Rosenow F, Knake S (2012) Diffusion tensor imaging in episodic cluster headache. *Headache* 52:274–282
10. DaSilva AF, Granziera C, Tuch DS, Snyder J, Vincent M, Hadjikhani N (2007) Interictal alterations of the trigeminal somatosensory pathway and periaqueductal gray matter in migraine. *Neuroreport* 18:301–305
11. Geha PY, Baliki MN, Harden RN, Bauer WR, Parrish TB, Apkarian AV (2008) The brain in chronic CRPS pain: abnormal gray-white matter interactions in emotional and autonomic regions. *Neuron* 60:570–581
12. Lutz J, Jager L, de Quervain D, Krauseneck T, Padberg F, Wichnialek M, Beyer A, Stahl R, Zirngibl B, Morhard D, Reiser M, Schelling G (2008) White and gray matter abnormalities in the brain of patients with fibromyalgia: a diffusion-tensor and volumetric imaging study. *Arthritis Rheum* 58:3960–3969
13. Gustin SM, Peck CC, Wilcox SL, Nash PG, Murray GM, Henderson LA (2011) Different pain, different brain: thalamic anatomy in neuropathic and non-neuropathic chronic pain syndromes. *J Neurosci* 31:5956–5964
14. Obermann M, Rodriguez-Raecke R, Naegel S, Holle D, Mueller D, Yoon MS, Theysohn N, Blex S, Diener HC, Katsarava Z (2013) Gray matter volume reduction reflects chronic pain in trigeminal neuralgia. *Neuroimage* 74:352–358
15. Smith SM, Jenkinson M, Woolrich MW, Beckmann CF, Behrens TE, Johansen-Berg H, Bannister PR, De LM, Drobnjak I, Flitney DE, Niazy RK, Saunders J, Vickers J, Zhang Y, De SN, Brady JM, Matthews PM (2004) Advances in functional and structural MR image analysis and implementation as FSL. *Neuroimage* 23(Suppl 1):S208–S219
16. Smith SM, Jenkinson M, Johansen-Berg H, Rueckert D, Nichols TE, Mackay CE, Watkins KE, Ciccarelli O, Cader MZ, Matthews PM, Behrens TE (2006) Tract-based spatial statistics: voxelwise analysis of multi-subject diffusion data. *Neuroimage* 31:1487–1505
17. Rueckert D, Sonoda LI, Hayes C, Hill DL, Leach MO, Hawkes DJ (1999) Nonrigid registration using free-form deformations: application to breast MR images. *IEEE Trans Med Imaging* 18:712–721
18. Fischl B, Dale AM (2000) Measuring the thickness of the human cerebral cortex from magnetic resonance images. *Proc Natl Acad Sci USA* 97:11050–11055
19. Rosas HD, Liu AK, Hersch S, Glessner M, Ferrante RJ, Salat DH, Van Der KA, Jenkins BG, Dale AM, Fischl B (2002) Regional and progressive thinning of the cortical ribbon in Huntington's disease. *Neurology* 58:695–701
20. Salat DH, Buckner RL, Snyder AZ, Greve DN, Desikan RS, Busa E, Morris JC, Dale AM, Fischl B (2004) Thinning of the cerebral cortex in aging. *Cereb Cortex* 14:721–730
21. Bowsher D, Miles JB, Hagggett CE, Eldridge PR (1997) Trigeminal neuralgia: a quantitative sensory perception threshold study in patients who had not undergone previous invasive procedures. *J Neurosurg* 86:190–192
22. Leandri M, Parodi CI, Favale E (1988) Early trigeminal evoked potentials in tumours of the base of the skull and trigeminal neuralgia. *Electroencephalogr Clin Neurophysiol* 71:114–124
23. Cruccu G, Leandri M, Iannetti GD, Mascia A, Romaniello A, Truini A, Galeotti F, Manfredi M (2001) Small-fiber dysfunction in trigeminal neuralgia: carbamazepine effect on laser-evoked potentials. *Neurology* 56:1722–1726
24. Rehberg B, Baars JH, Kotsch J, Koppe P, von Dincklage F (2012) Comparison of trigeminal and spinal modulation of pain and nociception. *Int J Neurosci* 122:298–304
25. Sahebgharani M, Hossein-Abad AA, Zarrindast MR (2006) On the mechanism of carbamazepine-induced antinociception in the formalin test. *Int J Neurosci* 116:1097–1113
26. Naseri K, Sabetkasaei M, Moini ZT, Saghaei E (2012) Carbamazepine potentiates morphine analgesia on postoperative pain in morphine-dependent rats. *Eur J Pharmacol* 674:332–336
27. Leal PR, Roch JA, Hermier M, Souza MA, Cristino-Filho G, Sindou M (2011) Structural abnormalities of the trigeminal root revealed by diffusion tensor imaging in patients with trigeminal neuralgia caused by neurovascular compression: a prospective, double-blind, controlled study. *Pain* 152:2357–2364
28. Farina S, Valeriani M, Rosso T, Aglioti S, Tamburin S, Fiaschi A, Tinazzi M (2001) Transient inhibition of the human motor cortex by capsaicin-induced pain. A study with transcranial magnetic stimulation. *Neurosci Lett* 314:97–101
29. Romaniello A, Cruccu G, McMillan AS, Arendt-Nielsen L, Svensson P (2000) Effect of experimental pain from trigeminal muscle and skin on motor cortex excitability in humans. *Brain Res* 882:120–127
30. Svensson P, Miles TS, McKay D, Ridding MC (2003) Suppression of motor evoked potentials in a hand muscle following prolonged painful stimulation. *Eur J Pain* 7:55–62



31. DaSilva AF, Becerra L, Pendse G, Chizh B, Tully S, Borsook D (2008) Colocalized structural and functional changes in the cortex of patients with trigeminal neuropathic pain. *PLoS One* 3(10):e3396
32. Cheshire WP (2003) Trigeminal neuralgia feigns the terrorist. *Cephalalgia* 23:230
33. Tolle T, Dukes E, Sadosky A (2006) Patient burden of trigeminal neuralgia: results from a cross-sectional survey of health state impairment and treatment patterns in six European countries. *Pain Pract* 6:153–160
34. May A (2011) Structural brain imaging: a window into chronic pain. *Neuroscientist* 17:209–220
35. Hutton C, Draganski B, Ashburner J, Weiskopf N (2009) A comparison between voxel-based cortical thickness and voxel-based morphometry in normal aging. *Neuroimage* 48:371–380
36. Calvert GA (2001) Crossmodal processing in the human brain: insights from functional neuroimaging studies. *Cereb Cortex* 11:1110–1123
37. Price DD (2000) Psychological and neural mechanisms of the affective dimension of pain. *Science* 288:1769–1772
38. de Leeuw R, Davis CE, Albuquerque R, Carlson CR, Andersen AH (2006) Brain activity during stimulation of the trigeminal nerve with noxious heat. *Oral Surg Oral Med Oral Pathol Oral Radiol Endod* 102:750–757
39. Fulbright RK, Troche CJ, Skudlarski P, Gore JC, Wexler BE (2001) Functional MR imaging of regional brain activation associated with the affective experience of pain. *Am J Roentgenol* 177:1205–1210
40. Veldhuijzen DS, Nemenov MI, Keaser M, Zhuo J, Gullapalli RP, Greenspan JD (2009) Differential brain activation associated with laser-evoked burning and pricking pain: An event-related fMRI study. *Pain* 141:104–113
41. Stern J, Jeanmonod D, Sarnthein J (2006) Persistent EEG overactivation in the cortical pain matrix of neurogenic pain patients. *Neuroimage* 31:721–731
42. Absinta M, Rocca MA, Colombo B, Falini A, Comi G, Filippi M (2012) Selective decreased grey matter volume of the pain-matrix network in cluster headache. *Cephalalgia* 32:109–115
43. Peelen MV, Downing PE (2005) Within-subject reproducibility of category-specific visual activation with functional MRI. *Hum Brain Mapp* 25:402–408
44. Buvanendran A, Ali A, Stoub TR, Berger RA, Kroin JS (2007) The use of brain positron emission tomography to identify sites of postoperative pain processing with and without epidural analgesia. *Anesth Analg* 105:1784–1786
45. Minassian AT, Ricalens E, Humbert S, Duc F, Aube C, Beydon L (2013) Dissociating Anticipation from perception: Acute pain activates default mode network. *Hum Brain Mapp* 34(9):2228–2243
46. Rocca MA, Messina R, Colombo B, Falini A, Comi G, Filippi M (2014) Structural brain MRI abnormalities in pediatric patients with migraine. *J Neurol* 261(2):350–357
47. Basselin M, Villacreses NE, Chen M, Bell JM, Rapoport SI (2007) Chronic carbamazepine administration reduces N-Methyl-D-Aspartate receptor-initiated signaling via arachidonic acid in rat brain. *Biol Psychiatry* 62(8):934–943
48. Rodriguez-Raecke R, Niemeier A, Ihle K, Ruether W, May A (2009) Brain gray matter decrease in chronic pain is the consequence and not the cause of pain. *J Neurosci* 29:13746–13750

doi:10.1186/1129-2377-15-17

**Cite this article as:** Parise et al.: Cuneus and fusiform cortices thickness is reduced in trigeminal neuralgia. *The Journal of Headache and Pain* 2014 15:17.

**Submit your manuscript to a SpringerOpen<sup>®</sup> journal and benefit from:**

- Convenient online submission
- Rigorous peer review
- Immediate publication on acceptance
- Open access: articles freely available online
- High visibility within the field
- Retaining the copyright to your article

---

Submit your next manuscript at ► [springeropen.com](http://springeropen.com)

---